

# Histopathologic Assessment of Healed Osteochondral Fractures

Mehmet S. Binnet, M.D., Ilksen Gürkan, M.D., Ataç Karakaş, M.D.,  
Cengiz Yılmaz, M.D., Selim Erekul, M.D., and Cem Çetin, M.D.

---

**Purpose:** To assess the histopathologic features of healed tissue to define its biological and biomechanical properties after internal fixation of osteochondral fractures. **Type of Study:** Cohort study. **Methods:** The general principle of management of detached acute osteochondral fractures is reattachment of the fragment by internal fixation, but the opinions on the quality and structure of the healed tissue that will be obtained after treatment is controversial. This study included 13 patients with acute osteochondral fractures who were treated arthroscopically and had surgical fixation providing joint-surface congruity. Patients with osteochondral fractures too small for fixation or with the overlying cartilage frayed, and patients with associated injuries were excluded from the study. The mean age of patients was 17 years (9 to 24 years). In 2 cases the fractures were localized at medial, in 7 at lateral femoral condyles, and in 4 at the patella. Internal fixation materials were K-wires for 1 case, Herbert screws for 3, and mini cancellous screws for 9 cases. The mean follow-up period was 6.3 years (3 to 13 years). On second-look arthroscopy, congruity of the joint surfaces and healed fractures was observed in all cases. Beside removal of the implant, punch biopsies were performed extending to the osteochondral junction; biopsy specimens were taken from the junction of the articular margin of the fragment and the edge of the remainder of the articular surface. **Results:** On histologic examination of the specimens, scarce mature chondrocytes among regenerative stroma, which dyed more eosinophilic than the basophilic chondral stroma and which had a chondrocyte-like appearance, were seen. Maturation of histologic architecture to hyaline or articular cartilage was not recorded in any of these cases. **Conclusions:** The clinical results did not correlate with the histologic findings. Despite the protected joint surface congruence, restoration of the hyaline cartilage at the chondral junctions could not be obtained. **Key Words:** Osteochondral—Fractures—Histopathology—Surgery.

---

**K**nee joint cartilage is an approximately 2 to 4 mm thick, avascular, alymphatic, aneural structure. Despite the well-known treatment modalities and healing potentials of ligaments and menisci following knee trauma, controversy exists about the repair process and the results of various treatments used in

chondral injuries. Osteochondral fractures occur in 2 different ways: (1) partially or totally displaced lesions involving either the chondral part or the whole osteochondral fragment, and (2) lesions with impaction of fragment into the medullary canal. The shape, size, viability, and content of the cells involved in these fractures vary with the depth from the articular surface, as well as the orientation of the collagen fibrils. Although important in remodalization of the extracellular matrix, chondrocytes have limited repair capacities.<sup>1</sup> Besides, antiadhesive properties of proteoglycans exert adverse effects in the repair process of isolated chondral injuries.<sup>2</sup> It is mandatory to assess the repair process and to determine appropriate treatment options because of the progressive nature of these kinds of injuries.

---

*From the Departments of Orthopedics and Traumatology (M.S.B., I.G., A.K., C.Y.); Pathology (S.E.); and Sports Medicine (C.C.), University of Ankara Medical School, Ankara, Turkey.*

*Address correspondence and reprint requests to Mehmet S. Binnet, M.D., A.Ü. İbni Sina Hastanesi Ortopedi ve Travmatoloji Anabilim Dalı, Ankara, Turkey. E-mail: msbinnet@diyalup.ankara.edu.tr*

*© 2001 by the Arthroscopy Association of North America  
0749-8063/01/1703-2477\$35.00/0  
doi:10.1053/jars.2001.21245*

Osteochondral fractures, including various sizes of subchondral bone, carry different properties when compared with the unsatisfactory treatment results of isolated chondral injuries. Considering response to treatment, the best prognosis is with this group of chondral injuries. The presence of the blood and blood-related factors originating from the fracture hematoma formed by the separation of the bone fragment from the subchondral surface creates differences in the repair process. Fibroblasts and collagen fibrils appear in the hemorrhagic fluid during the first few days following injury.<sup>1</sup> In 2 weeks, metaplasia of the mesenchymal cells to chondrocytes continues with extracellular matrix secretion, and at 6 months, the repair process is complete.<sup>3,4</sup> But the effectiveness of this inflammatory response depends on the applied treatment. Also, the quality and the structure of the healed tissue differ due to the treatment modality.

In this study, we analyzed this repair process in patients who had acute osteochondral fractures and had surgical fixation providing joint surface congruity. We have assessed the histopathologic features of the chondral fusion tissues. The aim of this study was to highlight the biologic and biomechanical properties of this tissue.

## METHODS

Between 1986 and 1996, 13 acute and isolated osteochondral fracture cases were treated in the first week following injury with internal fixation at the Department of Orthopedics and Traumatology, University of Ankara School of Medicine Ibn-I Sina Hospital. The study includes only patients who had osteochondral fractures with sufficient size of chondral

surface to allow rigid internal fixation. Patients with osteochondral fractures too small for fixation or with fragments having the overlying cartilage frayed, and patients with associated injuries were eliminated from the study.

The mean age of the patients at the time of injury was 17 years (range 9 to 24 years); there were 7 female and 6 male patients. Sports-related activity was the mechanism of injury in 9 cases. Of these, 2 experienced rotational trauma while dancing and turning around on 1 foot. None of these patients participated in professional sports activities. Four played soccer for recreational purposes. Osteochondral fractures developed in a traffic accident in 1 case and during daily living activities in 3 cases. In all of these cases, the reason for application to the hospital was hemarthrosis and limitation of motion of the knee following the trauma. Localization of the fractures is presented in Table 1.

The average time between clinical and radiological diagnosis and surgery was 2.7 days (range, 1 to 6 days). Owing to the size of the fragment, conventional radiographs were able to show the osteochondral fractures. The surgical procedure was performed by the same author (M.S.B.) via arthrotomy in 10 patients and arthroscopically in 3.

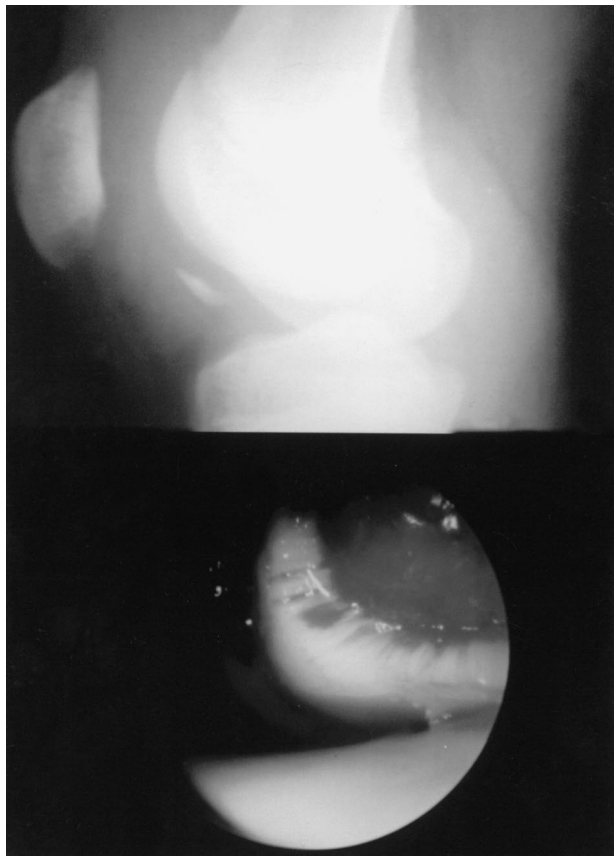
The surgical procedure started with observation of the intra-articular injuries after draining the hematoma. Then, determination of the size of the osteochondral fracture and its localization was made. Following the debridement of the hematoma and the debris over the fracture site, anatomic reduction of the fragment under direct visualization was performed. We chose different fixation materials for stable fixation. To avoid any rigorous damage to the epiphyseal

TABLE 1. *Distribution of the Lesions and Treatment Procedures of All Patients in the Series*

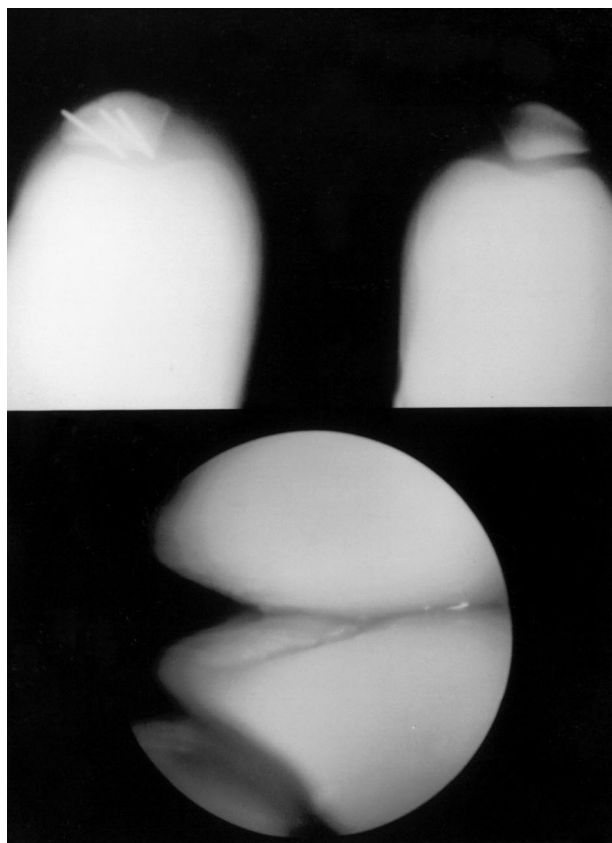
Pt.	Age (yr)	Localization	Fixation	Lysholm Score	Second-Look (mo)	Follow-Up (yr)
1	9	Patella	K-wires	89	2	3
2	17	Patella	Herbert screw	85	10	3
3	13	Patella	Herbert screw	89	4.5	6
4	11	Patella	Herbert screw	93	6	4
5	13	Medial femoral condyle	AO/ASIF screw	93	12	5
6	19	Medial femoral condyle	AO/ASIF screw	79	8	9
7	24	Lateral femoral condyle	AO/ASIF screw	75	120	13
8	13	Lateral femoral condyle	AO/ASIF screw	93	2	8
9	20	Lateral femoral condyle	AO/ASIF screw	74	3	3
10	19	Lateral femoral condyle	AO/ASIF screw	84	2	7
11	18	Lateral femoral condyle	AO/ASIF screw	89	2	9
12	20	Lateral femoral condyle	AO/ASIF screw	97	2	7
13	21	Lateral femoral condyle	AO/ASIF screw	79	12	5

cartilage and to be minimally invasive, K-wires were used for the youngest case with patellar involvement (Figs 1-5), whereas Herbert screws were used for the other 3 patellar-localized lesions (Figs 6 and 7), and AO/ASIF mini cancellous screws for the 9 patients with femoral condyle involvement (Figs 8-14). Cannulated AO/ASIF mini cancellous screws were used in the arthroscopically treated cases. Surgery was terminated once the decision was made that fixation was stable enough and there was no unstable cartilage structure.

The same postoperative protocol was used for the whole study group, consisting of cryotherapy, an intra-articular hemovac drain for 24 hours, continuous passive motion while hospitalized, and a functional hinged knee brace. Early range of motion was encouraged in all patients. The initiation of range of motion exercises aims at proper nutrition of the articular cartilage as well as restoration of a normal arc of motion. Weight bearing was not allowed for the first 6 postoperative weeks; during this time, crutches were used.



**FIGURE 1.** Radiographic and arthroscopic view of an osteochondral fracture separated from the patella of a 9-year-old male patient.

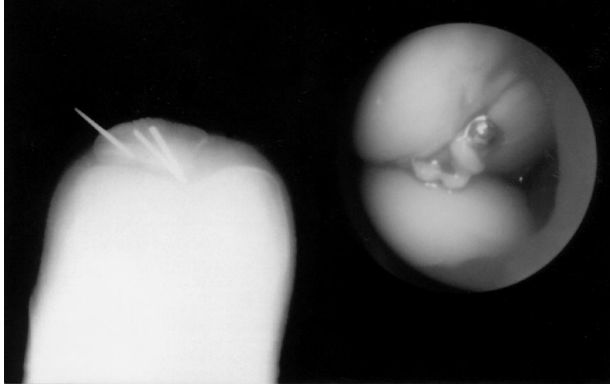


**FIGURE 2.** The osteochondral fracture of the patient at Fig 1 was fixed with 3 K-wires so as not to harm the epiphyseal nucleus. Postoperative tangential radiograph and arthroscopic view of the joint after fixation are shown.

Gradual weight bearing was allowed for the following 4 weeks depending on the fusion status of the fracture. After this time, full weight bearing was allowed.

Progressive muscular strengthening was recommended for all patients. For the first 2 weeks passive assisted exercises and, thereafter, active exercises were applied. In the arthroscopically treated group, these exercises could be started much earlier and, after these, aggressive active strengthening exercises were continued. Patients were allowed to return to sports at 6 months.

During follow-up, patients were given a questionnaire that evaluated the efficacy of the procedure and a Lysholm knee score was used to assess the results. Any abnormal clinical findings, complaints, and documented quadriceps atrophy were recorded. At 6 weeks, and at 3, 6, and 12 months, radiographs were taken. In addition to anteroposterior and lateral views, an axial patellar view was routinely used for the investigation of the lateral femoral condyle and the



**FIGURE 3.** The same patient developed bursitis over the patella 8 weeks postoperatively and spontaneous outward migration of the K-wire was observed. In a second surgical procedure, the bursitis tissue was excised and the K-wire removed. Arthroscopic examination revealed healed osteochondral fracture with lack of union at chondral junction regions.

articular surface of the patella, whereas a preoperative investigation consists of the 4 views (anteroposterior, lateral, axial patellar, and tunnel views). Any increase in the density of the subchondral bone, any irregularity in the articular surface or bony defects, and any visible fragmentation with total or partial detachment were looked for by comparing the follow-up radiographs.

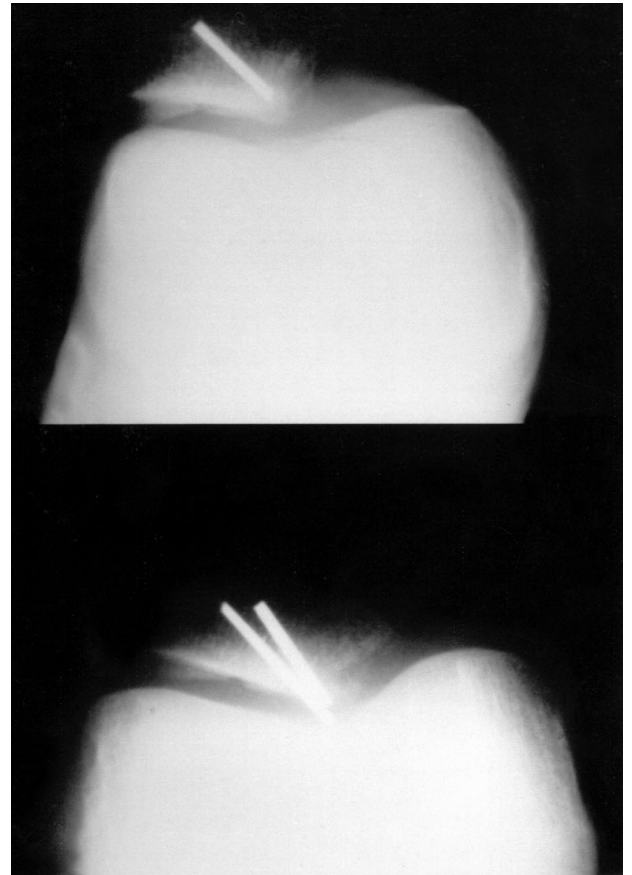
## RESULTS

The average clinical and radiologic follow-up time was 6.3 years (range, 3 to 13 years). In evaluating the functional status of the patients with a questionnaire, we received the answers "I can do nearly everything I want to with my joint" from 8 patients, and "I am restricted and a lot of things I want to do with my joint are not possible" from 5 patients. The activity level of the patients varied from occasional participation in recreational sports activities for 5, to living a sedentary life for the remaining 8 patients.

On follow-up examinations and at the last control, 9 of the patients had tenderness on palpation at the fracture localization. Only 3 patients had pain during vigorous activities. Of these 3, 2 had the pain localized around the medial joint line and 1 around medial and lateral joint line. Ten patients had 20 to 40 mL of hydroarthrosis for 8 to 12 weeks postoperatively. The hydroarthrosis disappeared following removal of the fixation material. At the last follow-up controls, 3 of the patients complained of developing hydroarthrosis during aggressive activation.

Restriction in range of motion was observed in none of the cases. Quadriceps muscle atrophy, which developed following the index procedure, continued to exist for 6.5 months (range, 3 to 11 months) in 7 of the cases. Crepitation in the patellofemoral joint was recorded in their last controls of 5 patients. On radiographic examinations, we encountered moderate narrowing of the medial joint line and osteophyte formation in 1 patient (Fig 11) (case 7), and flattening in the medial joint line, osteosclerosis, and narrowing in 3 patients.

Tangential radiographs of all of the patellar localized fracture cases showed patellar joint surface irregularities throughout all the follow-up controls (Figs 4, 5, and 7). In these cases, the fractures had solid fusion and no problems were encountered with weight bearing. In the patient who had fixation with K-wires (case 1), the wire dislocated spontaneously developing a



**FIGURE 4.** Two years postoperatively, the K-wire, which had migrated into the joint, was surgically removed. At this time, the radiologic joint surface irregularity was still present. The same findings were also shown on the 3-year postoperative tangential radiograph.

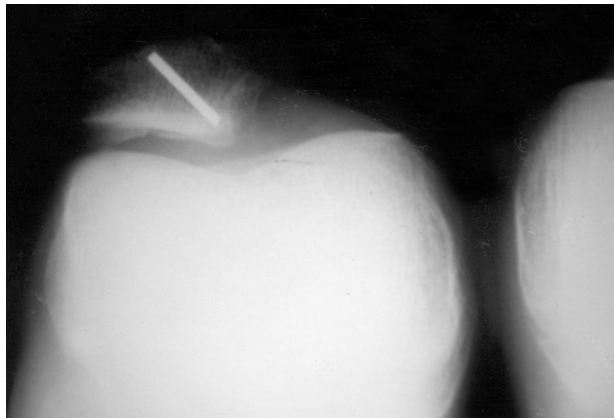


FIGURE 5. Five-year postoperative radiograph of the same patient.

bursa over itself (Fig 3). We performed a second operation for removal of the wires and excision of the bursa.

All patients were recommended to apply for implant removal and second-look arthroscopy 8 weeks after the initial surgery. Because the procedure was an elective one and had to be arranged around available time away from school and work of the patient, a certain timing protocol could not be achieved. The time between initial surgery and the second-look procedure ranged between 2 to 12 months except for 1 patient (case 7) who had undergone the procedure after 10 years of follow-up. The second-look procedure consisted of arthroscopic implant removal and punch biopsy. The 2-mm diameter cylindrical biopsy specimens, including the subchondral bone, were taken from the cartilaginous edge of the osteochondral fracture fragment (Fig 15).

On the second-look arthroscopic procedures, we observed congruity of the joint surfaces and healed fractures in all cases. Because of the bony fusion at the subchondral surface, all fracture lines showed intact smooth surfaces. None of the fragments had instability or separation. Despite congruity of the articular surface, 9 cases revealed softening of the cartilage-cartilage junction on examination with a probe. Actually, the junction of the cartilage surfaces in these cases were fibrillated. In 4 of the cases, the junctions had small scattered fissures or cracks, but were stable.

On histologic examination of these specimens, scarce mature chondrocytes among regenerative stroma, which dyed more eosinophilic than the basophilic chondral stroma and which had a chondrocyte-like appearance, were seen. The underlying bone tissue had irregular

proliferation, which is a determinant of the healing process (Fig 14). Despite the difference in obtaining time of the biopsies, findings were consistent throughout all the cases, including the latest case (10 years after the initial surgery). After treatment, regeneration of normal hyaline articular cartilage in junctional areas that duplicated the previous original one could not be seen in any of the cases. The clinical results did not correlate with the histologic findings.

## DISCUSSION

An intact cartilage structure of the knee joint has the ability to withstand loads as 5 times the body weight.<sup>5</sup> This is why obtaining structural integrity of the joint surfaces is the major goal of treatment of the osteochondral pathologies. Otherwise, early degenerative changes are inevitable because of the disturbed weight transfer and morphology of the joint surfaces. Osteochondral injuries having fragments larger than 3 mm are reported

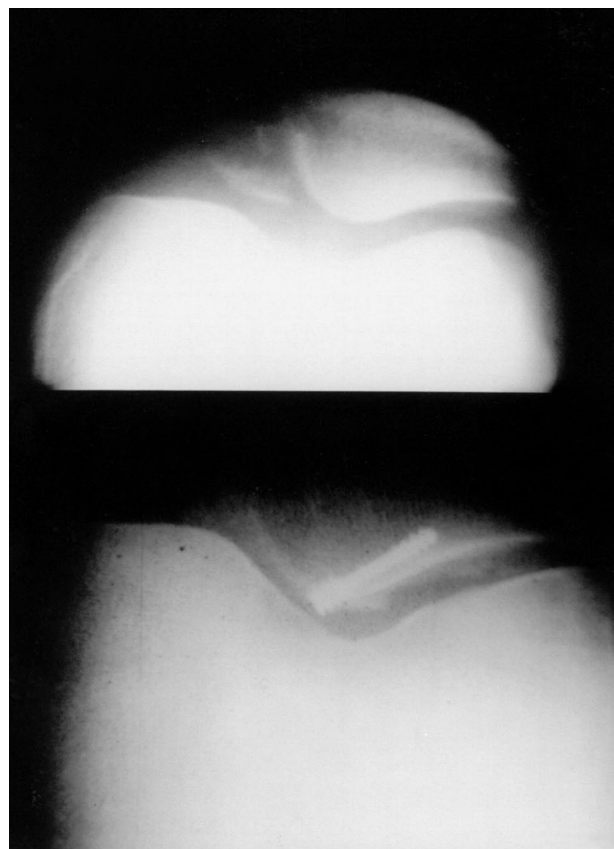


FIGURE 6. A 6-month postoperative tangential radiograph showing the patellar joint surface of an 18-year-old male patient whose patellar osteochondral fracture was fixated with a Herbert screw.

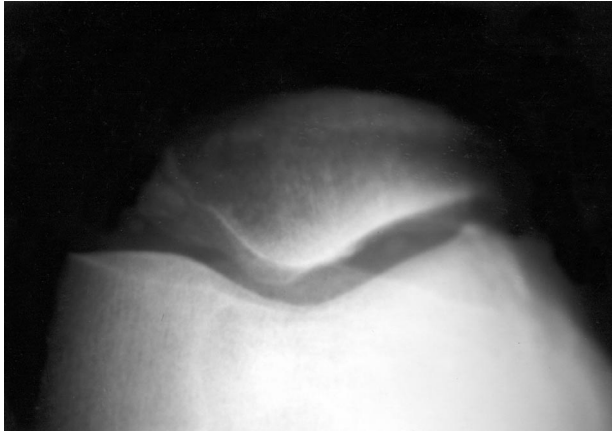


FIGURE 7. Tangential radiograph of the same patient taken after the removal of the Herbert screw 6 years after the index procedure.

not to have the possibility of spontaneous healing.<sup>6</sup> Relatively large osteochondral separations allow fixation and, if the injury is located at the weight-bearing surfaces, anatomic reduction followed by stable fixation is mandatory.<sup>7,8</sup> There still is no consensus about the relationship between the presence of the fracture at weight-bearing localizations and the treatment results.<sup>9,10</sup>

Localization and size of the injury, and the age of the patient affect the healing possibility of the osteochondral fractures. Injuries occurring when the epiphyses are still open have a better chance and rate of healing.<sup>11</sup> As age increases, both the possibility and rate of healing decrease.<sup>2,12</sup> We have encountered no full separation of the fragments on our postoperative follow-up controls. We relate this result to our patient population, which consists largely of adolescents. The reason for the relatively frequent appearance of the

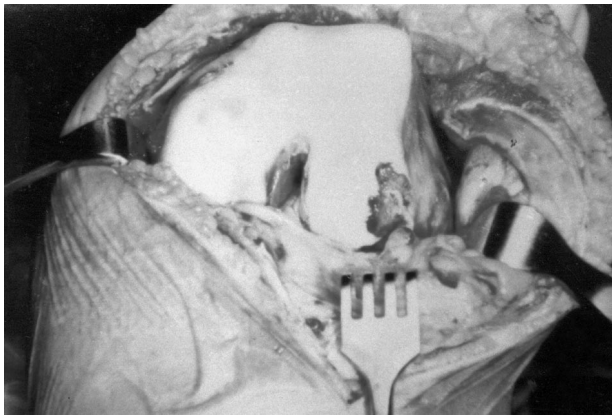


FIGURE 8. Intraoperative view of the osteochondral fracture at the lateral femoral condyle of the first case in our series.

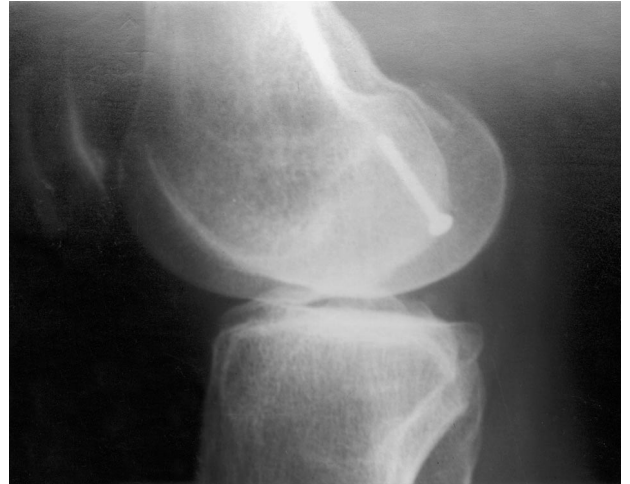

FIGURE 9. Healed osteochondral fracture seen on a lateral radiograph of the same patient 3 years after the operation.

osteochondral fractures in adolescents is the weakness of the calcified zone of the cartilage neighboring the subchondral bone.<sup>7</sup>

The most frequent site of fracture in our series was the lateral femoral condyle, followed by the patellar chondral surface. As we have stated in our previous studies, the major predisposing factor for the mentioned injury is the patellofemoral incongruity.<sup>7,8</sup> Pathologic lateral displacement of the patella following rotational stresses causes injuries of various severity primarily on the lateral condyle of the femur and then on the joint surface of the

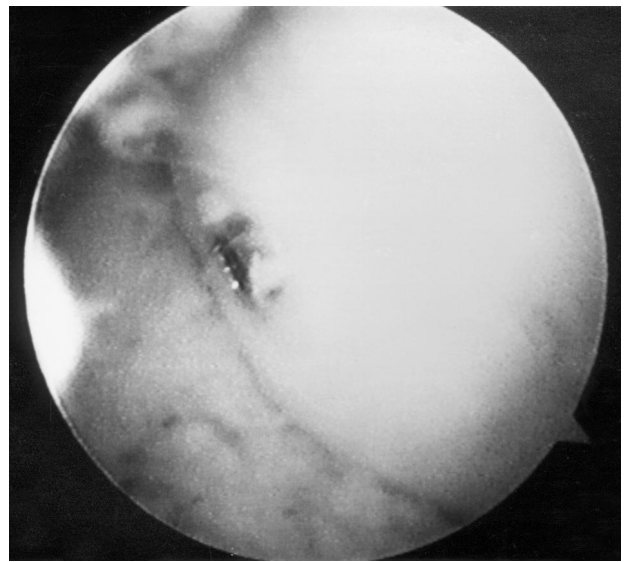
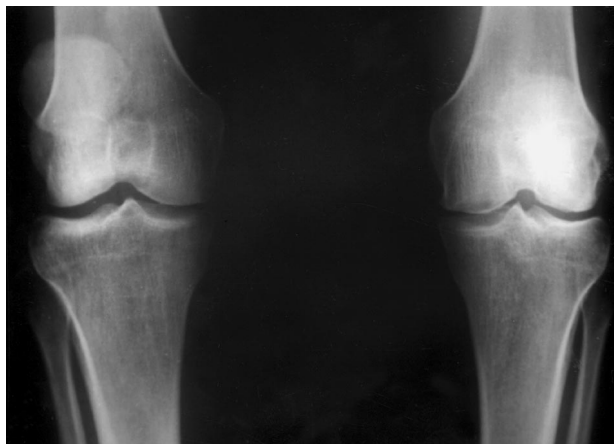


FIGURE 10. Arthroscopic view of the same case before removal of the screw.

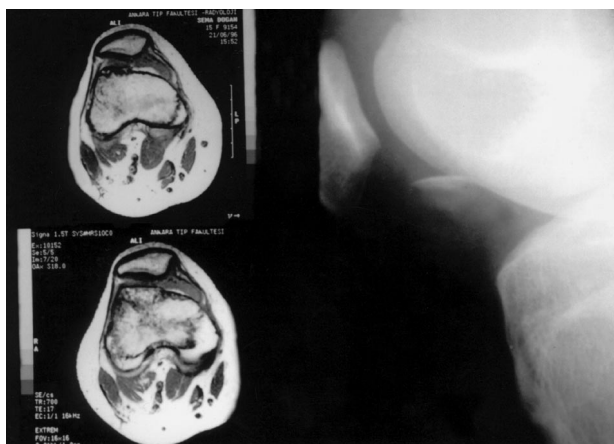


**FIGURE 11.** Standing anteroposterior comparison radiographs of the same patient 13 years after the index procedure, and 10 years after the removal of the screw.

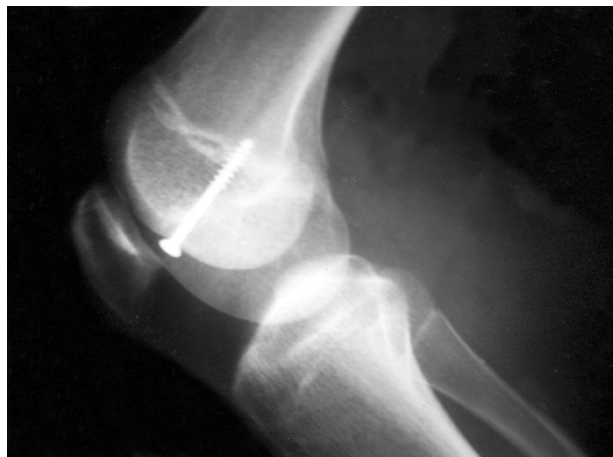patella.<sup>7,8</sup> The most severe forms of this kind of injury are those causing osteochondral fractures. The localizations of the injuries in our cases confirm the patellofemoral pathology origin.

The shorter duration of time between injury and the surgery, in patients who are treated surgically, has been reported as 1 of the factors that contributes to better results.<sup>13</sup> For all the cases treated, we aimed to perform the surgical procedure as early as possible, to prevent aggression of the injury causing further chronic chondral injury.

Whatever the fixation method is, early motion is essential for recovery in osteochondral fractures. Early passive motion induces chondroitin sulfate se-



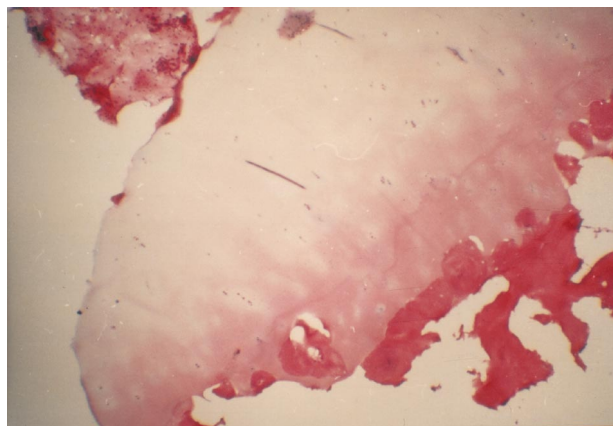
**FIGURE 12.** Lateral radiograph and magnetic resonance imaging views of a 14-year-old female patient who had an osteochondral fracture at the lateral femoral condyle caused by rotational trauma.



**FIGURE 13.** Lateral radiograph 1 year postoperatively of the same patient.

cretion, which helps form a better matrix. It has been stated that a smooth chondral surface is only possible by application of early motion.<sup>14-16</sup> We believe the lack of restriction in range of motion of cases depends on meticulous care shown for this principle.

Even after an appropriate treatment protocol despite the union on bony surfaces, chondral junctions only heal partially if at all.<sup>2,3,17</sup> Inability to obtain regular hyaline cartilage at union zones depends on lack of high organization levels of the collagen at these areas.<sup>18</sup> Chondral union being limited to only fibrous union in some cases is shown to be possible with higher quality tissues.<sup>19-21</sup>



**FIGURE 14.** Histopathologic view of the 2-mm cylindrical biopsy material obtained during screw removal from the same patient showing fibrous cartilage formation at the junction of sound articular cartilage and the chondral part of the osteochondral fragment. Note the presence of scarce mature chondrocytes among regenerative stroma that dyes more eosinophilic than the basophilic chondral stroma, chondrocyte-like appearance.

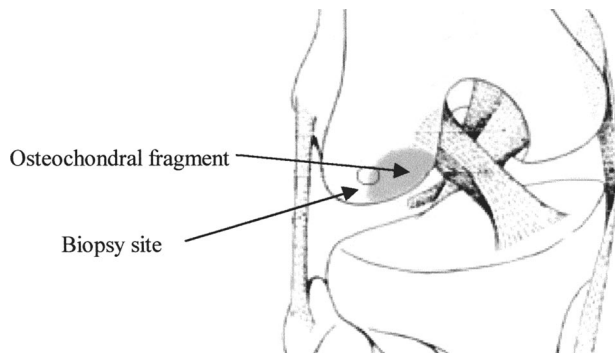


FIGURE 15. The area from which biopsy specimens are taken.

Despite the fact that this tissue obtained from the cartilage-cartilage junction is inferior to normal hyaline cartilage mechanically, chemically, and structurally, and is 2 to 3 times weaker, second-look procedure examinations showed us that this tissue could still provide stability to the fragment, and these inferior properties cannot be referred to the quality of the tissue in the center of the fragment.<sup>2,11</sup> Although the junctional cartilage does not have the same properties with the hyaline cartilage, we have seen that stability of the fragment is the most important factor in obtaining satisfactory clinical results. The evidence that the clinical results vary considerably among cases can be attributed to the variation of treatment types.

The presence of even a small piece of cancellous bone enhances results of treatment of osteochondral fractures involving wide cartilaginous surfaces. This is why it is wise to make use of the chance of healing provided by the blood and blood-related factors. By the help of stable fixation, it is possible to save wide areas of joint surface.

Neither after application of various treatment modalities, nor after the progression of the fractures to chronic cartilage pathologies, is it possible to gain original joint surface configuration. In this study, we have seen that, despite the protected joint surface congruence, restoration of the hyaline cartilage at the chondral junctions could not be obtained. We believe that, beside factors that may be able to enhance chondral healing (which we currently researching), internal fixation seems still to be one of the most effective treatment methods.

## REFERENCES

1. Buckwalter JA, Rosenberg L, Coutts R, Hunziker E, Reddi AH, Mow V. Articular cartilage: Injury and repair. In: Woo SL, Buckwalter JA, eds. *Injury and repair of the musculoskeletal soft tissues*. Chicago: American Academy of Orthopaedic Surgeons, 1988:465-482.

2. Messner K, Wei X. Healing chondral injuries. *Sports Med Arthrosc Rev* 1998;6:13-24.
3. Messner K, Gillquist J. Synthetic implants for the repair of osteochondral defects of the medial femoral condyle. A biomechanical and histological evaluation of the rabbit knee. *Biomaterials* 1993;14:513-521.
4. Messner K. Hydroxylapatite supported Dacron plugs for repair of isolated full thickness osteochondral defects of the rabbit femoral condyle. *J Biomed Mater Res* 1993;27:1527-1532.
5. Bergmann G, Graichen F, Rohlmann A. A hip joint during walking and running measured in two patients. *J Biomech* 1993;26:969-990.
6. Convery FR, Akeson WH, Keown GH. The repair of large defects. An experimental study in horses. *Clin Orthop* 1972; 82:253-262.
7. Binnet M, Demirtas M, Ates Y, Mergen E. Traumatic articular cartilage injuries of the knee. *Acta Orthop Traumatol Turc* 1991;25:326-329.
8. Binnet MS, Ates Y, Isiklar U. Arthroscopy in cartilage lesions of the knee joint [in Turkish]. *Artrroskopi ve Artroplasti Dergisi* 1989;1:33-40.
9. Bruns J, Kertsen P, Lierse W, Silbermann B. Autologous rib perichondral grafts in experimentally induced osteochondral lesions in the sheep knee joint. *Virchows Arch A Pathol Anat Histopathol* 1992;421:1-8.
10. DePalma AF, McKeever CD, Subin DK. Process of repair of articular cartilage demonstrated by histology and autoradiography with tritiated thymidine. *Clin Orthop* 1966;48:229-242.
11. Wei X, Gao J, Messner K. Maturation dependent repair of the untreated osteochondral defects in the rabbit knee joint. *J Biomed Mater Res* 1997;34:63-72.
12. Roth V, Mow V. The intrinsic tensile behavior of matrix of the bovine articular culture and its variation with age. *J Bone Joint Surg Am* 1980;62:1102-1117.
13. Mayer G, Seidlein H. Chondral and osteochondral fractures of the knee joint, treatment and result. *Arch Orthop Trauma* 1988;107:154-157.
14. O'Driscoll SW, Keeley FW, Salter RB. Durability of regenerated articular cartilage produced by free autologous periosteal grafts in major full thickness defects in joint surfaces under the influence of continuous passive motion. *J Bone Joint Surg Am* 1988;70:595-606.
15. O'Driscoll SW, Salter RB. The repair of major osteochondral defects in joint surfaces by neochondrogenesis with autogenous osteoperiosteal grafts stimulated by continuous passive motion. *Clin Orthop* 1986;208:131-140.
16. Shimizu T, Videman T, Shimazaki K, Mooney V. Experimental study on the repair of full thickness articular cartilage defects. Effects of varying periods of continuous passive motion, cage activity, and immobilization. *J Orthop Res* 1987;5: 187-197.
17. Mow VC, Ratcliffe A, Rossenwasser MP, Buckwalter JA. Experimental studies on repair of large osteochondral defects at a high weight bearing area of the knee joint. A tissue engineering study. *J Biomech Eng* 1991;113:198-207.
18. Mitchell N, Shepard N. The resurfacing of adult rabbit articular cartilage by multiple perforations through the subchondral bone. *J Bone Joint Surg Am* 1976;58:230-233.
19. Cheung H, Lynch KL, Johnson RP, Brewer BJ. In vitro synthesis of tissue specific type II collagen by healing cartilage. Short-term repair of cartilage by mature rabbits. *Arthritis Rheum* 1980;23:211-219.
20. Gomar-Sancho F, Orquin EG. Repair of osteochondral defects in articular weight bearing areas in the rabbit's knee. *Int Orthop* 1987;11:65-69.
21. Lohmander S. Proteoglycans of joint cartilage. *Baillieres Clin Rheumatol* 1988;2:37-62.